



PATIENT

Milly Perino

SPECIES

Canine

BREED

Golden Retriever

SEX

Female Spayed

AGE

1.3 years

WEIGHT

63lbs

PRESENTING CLINICAL SIGNS

History: Grade II/VI systolic murmur heard as a 10-week-old puppy in June 2021. Annual appointment July 2022, showed a grade II-III/VI systolic murmur. Otherwise, normal healthy dog.

ECHOCARDIOGRAM FINDINGS

2D, m-mode, color flow and Doppler imaging is available.

Left ventricle: The LV diameter is normal with adequate myocardial function. LV wall thicknesses are normal.

Left atrium: The left atrium is normal.

Mitral valve: The mitral valve is mildly thickened with no prolapse into the left atrial lumen. No mitral regurgitation.

Aortic valve/Aorta: The aortic valve is normal in morphology and mobility. Normal aortic outflow velocity; laminar flow. Trace aortic insufficiency.

Right ventricle: Normal right ventricular diameter and morphology indicating no overt evidence of pulmonary arterial hypertension.

Right atrium: Normal RA dimension.

Tricuspid valve: The tricuspid valve appears normal with no tricuspid regurgitation.

Pulmonic valve/Pulmonary artery: The pulmonic valve is normal in morphology and mobility. No pulmonic insufficiency. Normal RVOT velocity; laminar flow.

Pericardium/other: No pericardial or pleural effusion noted. No obvious cardiac masses.

Heart rhythm: ECG reveals a sinus rhythm with an average HR of 120bpm.

INTERPRETED BY

Maggie Machen
Lamy, DVM
DACVIM (Cardiology)

2-Dimensional Measurements

Ao diam (cm)	2.4
LA diam (cm)	2.5
LA:Ao (Swe)	1.1
IVS thickness (cm)	1.1
LVID diastole (cm)	3.8
PW thickness (cm)	1.1
LVID systole (cm)	2.5
FS (%)	31

Doppler Measurements

PV Vmax (m/s)	1.1
AoV Vmax (m/s)	1.6
MR Vmax (m/s)	NA
TR Vmax (m/s)	NA
TR PG (mmHg)	NA

IMAGING

PERFORMED BY

Pamela Harrigan,
RDCS

INTERPRETATION OF THE FINDINGS

Overtly normal cardiac structure and function. No cause of the murmur is identified in this study. Trivial MR is noted; however, this is unlikely to be heard on physical exam. In the absence of significant volume changes (dehydration) or anemia, other possibilities include a physiologic flow murmur only present with elevated heart rates, or a small flow abnormality not seen here. Baseline lab work is recommended if not recently performed. It is reasonable to monitor periodically via recheck echocardiography in the future, particularly should the murmur persist/progress. No significant valvular insufficiencies were noted, and no structural issues identified.

HOSPITAL NAME

Wood River Animal
Hospital

REFERRING VET

Dr. Plunkett

INVOICE

25503

DATE

7/22/22

RECOMMENDATIONS

- No cardiac medications are indicated at this time. Monitor for any development of cough, labored breathing or exercise intolerance.
- No cardiac contraindication for general anesthesia.



PATIENT

Milly Perino

SPECIES

Canine

BREED

Golden Retriever

SEX

Female Spayed

AGE

1.3 years

WEIGHT

63lbs

INTERPRETED BY

Maggie Machen
 Lamy, DVM
 DACVIM (Cardiology)

IMAGING

PERFORMED BY

Pamela Harrigan,
 RDCS

HOSPITAL NAME

Wood River Animal
 Hospital

REFERRING VET

Dr. Plunkett

INVOICE

25503

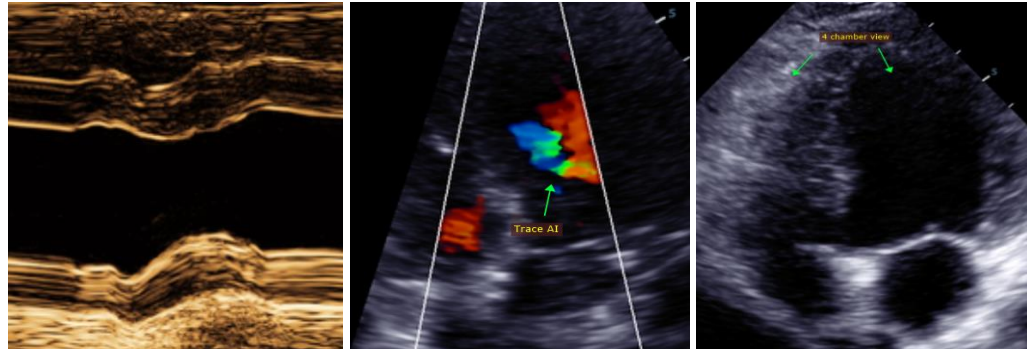
DATE

7/22/22

PLAN

- Recommend recheck echocardiogram in 12-18 months to screen for progression or development of concurrent cardiac disease that the preexisting murmur may mask.

IMAGES



The information and recommendations provided are based on the images presented by the referring veterinarian. No evaluation can be communicated regarding pathology that was not visible in the image/video clips provided.

Thank you for this referral. This report was generated using transcription software, and minor dictation errors may be present. If the clinical or image interpretation does not parallel your findings or if I can be of any further assistance, please contact me.

Maggie Machen Lamy, DVM
 Diplomate of the American College of Veterinary Internal Medicine (Cardiology)
 info@sonopath.com